

Peripheral intracranial aneurysms: management challenges in 60 consecutive cases

Clinical article

ERIC S. NUSSBAUM, M.D., MICHAEL T. MADISON, M.D., JAMES K. GODDARD, M.D.,
JEFFREY P. LASSIG, M.D., AND LESLIE A. NUSSBAUM, M.D., PH.D.

National Brain Aneurysm Center, St. Joseph's Hospital, St. Paul, Minnesota

Object. The authors report the management and outcomes of 55 patients with 60 intracranial aneurysms arising distal to the major branch points of the circle of Willis and vertebrobasilar system.

Methods. Between July 1997 and December 2006, the authors' neurovascular service treated 2021 intracranial aneurysms in 1850 patients. The database was reviewed retrospectively to identify peripherally located intracranial aneurysms. Aneurysms that were mycotic and aneurysms that were associated with either an arteriovenous malformation or an atrial myxoma were excluded from review.

Results. The authors encountered 60 peripheral intracranial aneurysms in 55 patients. There were 42 small, 7 large, and 11 giant lesions. Forty-one (68%) were unruptured, and 19 (32%) had bled. Fifty-three aneurysms were treated surgically by using direct clip reconstruction in 26, trapping or proximal occlusion with distal revascularization in 21, excision with end-to-end anastomosis in 3, and circumferential wrap/clip reconstruction in 3. Coils were used to treat 6 aneurysms, and 1 was treated by endovascular parent artery occlusion. Overall, 49 patients had good outcomes, 4 were left with new neurological deficits, and 2 died.

Conclusions. Peripherally situated intracranial aneurysms are rare lesions that present unique management challenges. Despite the fact that in the authors' experience these lesions were rarely treatable with simple clipping of the aneurysm neck or endovascular coil occlusion, preservation of the parent artery was possible in most cases, and the majority of patients had a good outcome. (DOI: 10.3171/2008.6.JNS0814)

KEY WORDS • aneurysm • brain • bypass procedure • dissection • stroke

MOST intracranial aneurysms are saccular lesions that arise at arterial branch points on the circle of Willis, at the bifurcation of the MCA, or at the origins of the major branches of the vertebrobasilar system. With the exception of distal ACA aneurysms arising at the origin of the pericallosal artery, true peripheral intracranial aneurysms occur rarely and have been described only cursorily in the neurosurgical literature.^{8,9,17,20–22,26,29,34,36} We report an unusually large series of patients with peripherally located intracranial aneurysms, describing management strategies and reviewing the literature regarding these lesions.

Abbreviations used in this paper: ACA = anterior cerebral artery; AICA = anterior inferior cerebellar artery; MCA = middle cerebral artery; OA = occipital artery; PCA = posterior cerebral artery; PICA = posterior inferior cerebellar artery; SAH = subarachnoid hemorrhage; SCA = superior cerebellar artery; STA = superficial temporal artery.

Methods

We retrospectively reviewed the records of all patients with intracranial aneurysms managed by our neurovascular service between July 1997 and December 2006. Among 2021 intracranial aneurysms in 1850 patients treated during this period, we identified 60 (2.97%) peripherally located intracranial aneurysms. We defined an aneurysm as peripheral if it arose distal to the MCA bifurcation or to the origins of the pericallosal artery, PCA, SCA, AICA, or PICA. Patients with peripherally located frontopolar artery and anterior temporal artery aneurysms were also included. Mycotic lesions and intracranial aneurysms associated with an arteriovenous malformation or an atrial myxoma were excluded. Hospital records, neuroimaging studies, operative reports, and follow-up clinic notes were complete and reviewed in all cases. Follow-up review ranged from 6 months to 8 years (average 3.2 years), and no patient was lost to follow-up review.

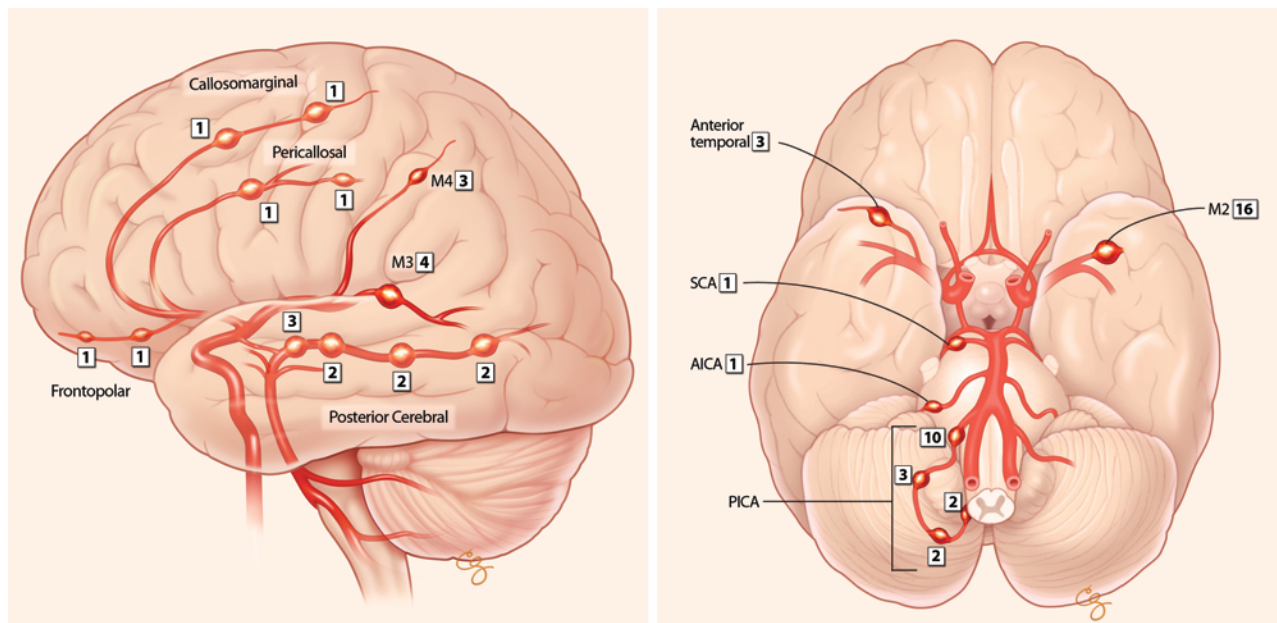


FIG. 1. Artist's drawings depicting lateral (*left*) and basal (*right*) views of the brain, including the number of peripheral aneurysms encountered in each location in this series. M2, M3, and M4 = second-, third-, and fourth-order branches of the MCA.

Results

We treated 60 peripheral intracranial aneurysms in 55 patients ranging in age from 5 to 84 years. Of these aneurysms, 26 were located on the MCA, 17 on the PICA, 9 on the PCA, 6 on the ACA, 1 on the SCA, and 1 on the AICA (Fig. 1). Forty-one aneurysms (68%) were unruptured and 19 (32%) had bled. There were 42 (70%) small (maximum diameter < 1 cm), 7 (12%) large (maximum diameter 1–2.5 cm), and 11 (18%) giant (maximum diameter > 2.5 cm) lesions. Fifty-four aneurysms (90%) were very wide necked or fusiform and were not associated with an arterial branch point. Eight patients had a second aneurysm, but only 5 of the 8 lesions were peripheral intracranial aneurysms; the other 3 weren't counted in this series.

Seven aneurysms (12%) were treated endovascularly. Of these, 6 had a narrow neck and were treated with direct coil embolization. One patient underwent endovascular parent artery occlusion across the neck of the aneurysm. Fifty-three aneurysms (88%) were treated surgically. The techniques used were direct clip reconstruction for 26, trapping or proximal occlusion with distal revascularization for 21, excision with end-to-end anastomosis for 3, and circumferential wrap/clip reconstruction for 3. The specific surgical approach in each case was dictated by the location of the aneurysm and the associated vascular anatomy. The MCA lesions were explored through a pterional craniotomy with preservation of the STA and wide splitting of the sylvian fissure. Distal ACA aneurysms were treated via a parasagittal interhemispheric approach. The PCA aneurysms were approached through an orbitozygomatic or subtemporal craniotomy, and a far-lateral suboccipital craniotomy was used for PICA aneurysms.

Using microsurgery or endovascular coil placement,

we were able to preserve or primarily reconstruct the parent artery in 38 cases (63%). Because of the uncertain adequacy of collateral supply, we usually performed distal revascularization when it was necessary to sacrifice the parent artery (21 of 22 cases). Interestingly, the involved parent artery was often found to be unusually large despite its peripheral location, which further tempered enthusiasm for isolated sacrifice without revascularization. The specific technique used for revascularization was tailored based on the individual anatomical considerations of each case.

In 3 cases, the parent artery was ectatic and redundant, allowing for excision with direct, end-to-end reanastomosis. In patients with peripheral MCA aneurysms that could not be reconstructed, the STA was usually anastomosed to the parent artery immediately distal to the aneurysm in an end-to-side fashion (Fig. 2). Patients with peripheral PICA aneurysms that could not be clipped underwent an OA-to-PICA bypass or PICA-PICA side-to-side anastomosis.²⁶ An OA-to-PCA bypass was used for patients undergoing PCA occlusion.³⁵

In 3 cases of peripheral PICA aneurysms, surgical exploration revealed brainstem perforating vessels arising from the fusiform, aneurysmal segment. In those instances, circumferential wrap/clip reconstruction was used, sparing the perforating vessels (Fig. 3).²⁵ This appeared to be a reasonable option, considering the potentially severe consequences of occluding perforating vessels in these rare cases.

Intraoperative angiography was performed in every case. For patients who underwent primary clip reconstruction, intraoperative angiography was extremely important in assessing the adequacy of aneurysmal obliteration and in excluding the presence of clip-induced parent artery

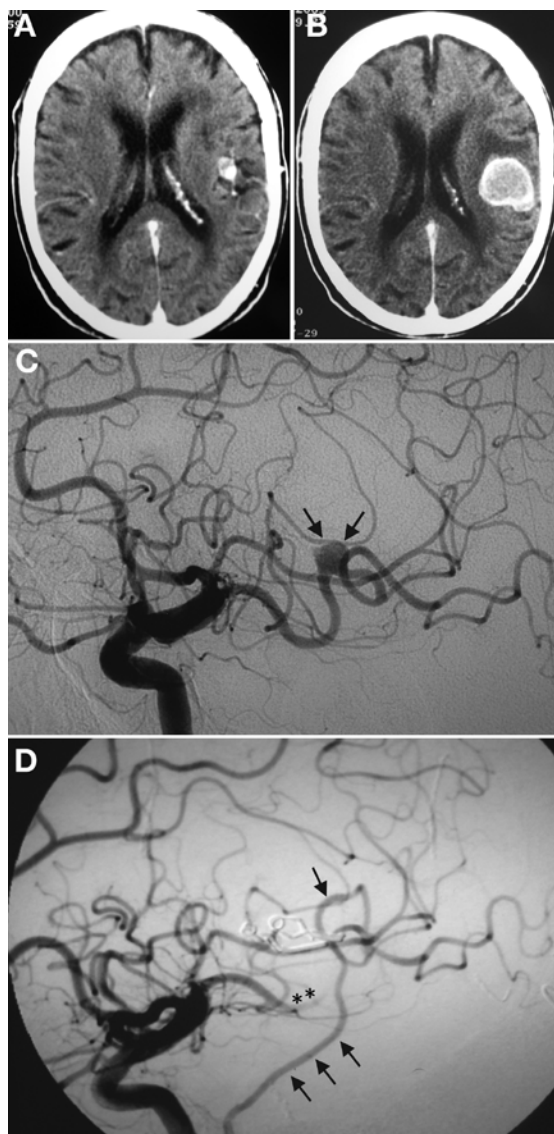


FIG. 2. Axial CT scans obtained in 2000 (A) and then in 2003 (B) demonstrate dramatic enlargement of a peripheral MCA aneurysm, with development of associated cerebral edema. Lateral digital subtraction angiographic image (C) demonstrates the filling portion of the irregular, fusiform lesion (arrows). Of note is the unusually large caliber of the parent artery given its peripheral location. Lateral intraoperative common carotid angiographic image (D) demonstrates trapping of the aneurysm with clips. The STA (3 arrows) has been anastomosed (single arrow) to the parent artery immediately distal to the clips and now irrigates the sacrificed parent artery. The parent artery demonstrates minimal retrograde thrombosis (asterisks). The aneurysm was opened and evacuated of thrombus, resulting in immediate postoperative improvement in the patient's severe, progressive speech difficulty.

stenosis. This was particularly useful in the treatment of larger and partially thrombosed lesions (Fig. 4). Based on intraoperative angiographic findings, clip repositioning or the placement of additional clips was required in 8 (31%) of 26 cases. For those patients undergoing distal revascularization, intraoperative angiography was used to confirm patency of the bypass before vascular sacrifice.

Overall, 49 patients had good outcomes, 4 developed neurological complications, and 2 died. One patient who died had presented in good condition with a giant PICA aneurysm. He underwent an OA-PICA bypass followed by trapping of the aneurysm. He tolerated surgery well without obvious postoperative deficit, but then developed severe aspiration pneumonia, acute respiratory distress syndrome, and multiple-system organ failure. Although he had passed a postoperative swallowing evaluation, it is possible that mild or delayed lower cranial nerve dysfunction may have contributed to this complication. The other patient who died had a severe SAH from a small peripheral MCA aneurysm that was clipped on an emergency basis at the time of decompressive hemicraniectomy for severe brain swelling. The patient never regained consciousness, and support was later withdrawn at the family's request.

Four patients developed neurological complications related to treatment of their aneurysms. An 86-year-old man with a giant, ruptured ACA (callosomarginal branch) aneurysm underwent endovascular parent-artery occlusion with coils deposited across the neck of the aneurysm without revascularization. He suffered a significant ischemic injury to his dominant premotor cortex, resulting in transient but severe hemiparesis and aphasia. Another patient with a ruptured giant PICA aneurysm underwent OA-PICA bypass and aneurysm excision. He experienced severe postoperative vasospasm and developed a pseudomeningocele and wound infection. He was left with long-standing vertigo and bilateral cranial nerve VI palsies. A 68-year-old man with a giant, dominant, peripheral MCA aneurysm developed postoperative focal seizures requiring long-term anticonvulsant therapy. Finally, a 57-year-old woman with a peripheral SCA aneurysm developed a partial cranial nerve IV palsy related to dissection of the nerve from the aneurysm neck to permit clip reconstruction. This condition had resolved by the time of a 9-month follow-up visit.

During the follow-up period, no patient rebled from a previously ruptured aneurysm or bled from a previously unruptured aneurysm. Two patients developed lower-extremity deep venous thrombosis requiring anticoagulation therapy. Eight patients required temporary external ventricular drainage for acute hydrocephalus after SAH; 3 ultimately underwent placement of a ventriculoperitoneal shunt.

Discussion

Few intracranial aneurysms arise distal to the major branch points of the circle of Willis and the vertebrobasilar system.^{3,8,18} Such peripherally situated aneurysms are often fusiform, may be unassociated with an arterial branch point, and reach large or giant size in a substantial percentage of cases.^{2,3,7,8} The fusiform nature and large size of many peripheral intracranial aneurysms substantially complicate treatment paradigms, in that many of these lesions cannot be managed by direct surgical clipping or simple coil embolization of the aneurysm sac.

Peripheral intracranial aneurysms may develop as a result of an arterial dissection or in response to unusual

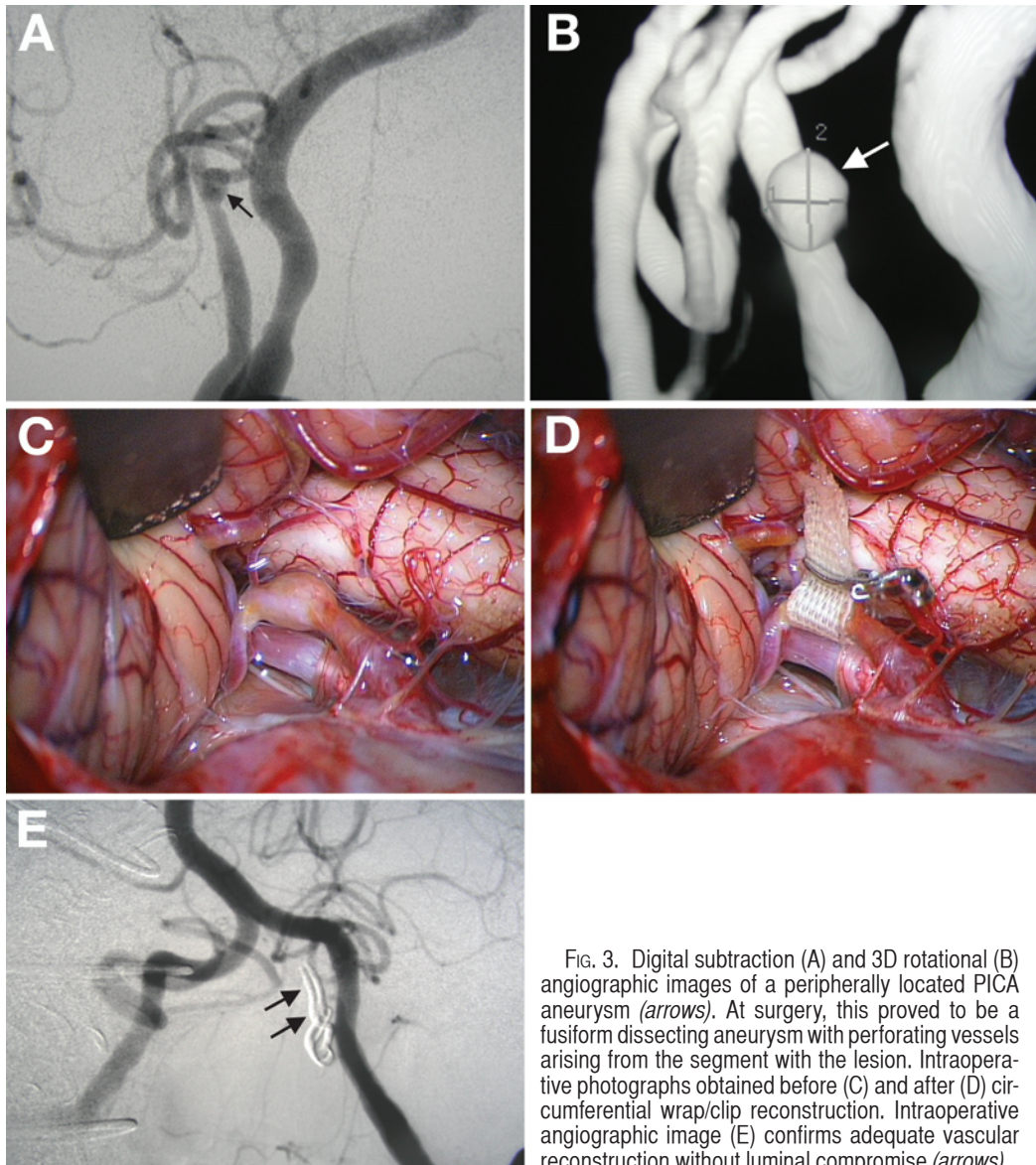


FIG. 3. Digital subtraction (A) and 3D rotational (B) angiographic images of a peripherally located PICA aneurysm (arrows). At surgery, this proved to be a fusiform dissecting aneurysm with perforating vessels arising from the segment with the lesion. Intraoperative photographs obtained before (C) and after (D) circumferential wrap/clip reconstruction. Intraoperative angiographic image (E) confirms adequate vascular reconstruction without luminal compromise (arrows).

hemodynamic stress, as may be seen in the presence of a high-flow arteriovenous malformation.^{7,16,21,24,27} Mycotic and oncotic aneurysms often develop in peripheral locations, presumably because they are embolic lesions.^{4,5,14} Peripheral intracranial aneurysms have also been reported to arise after cranial irradiation and in patients who have systemic disorders such as polyarteritis nodosa and Behçet disease.^{23,28,30,32} For reasons that are not clear, a disproportionate percentage of intracranial aneurysms identified in children occur in peripheral locations.^{3,7,8,12,29,31}

Management Considerations

Because of the relative rarity of peripheral intracranial aneurysms, clearcut guidelines for their management have not been established.^{2,3,8,10,26} Surgical options include direct clip reconstruction, vascular occlusion with or without distal revascularization, excision with end-to-end

anastomosis, or some form of wrapping.^{2,8,25,35} Endovascular options include coil embolization of those lesions that have a relatively narrow neck, stent-supported coil placement for wider-necked aneurysms, or parent-artery occlusion.^{3,10,11,18,37} Traditionally, most peripheral intracranial aneurysms managed endovascularly have been treated with parent artery occlusion.^{3,6,10,13} Although various forms of balloon test occlusion and amyntal testing have been described in conjunction with this management strategy, the results have been notoriously unreliable, and there is no test that can assess definitively the adequacy of collateral circulation in this setting.^{3,10,19}

We have considered coil embolization a reasonable option for those peripheral intracranial aneurysms that have a narrow neck. With the introduction of stent-supported coil placement, some of the wider-necked aneurysms that were treated surgically early in our series

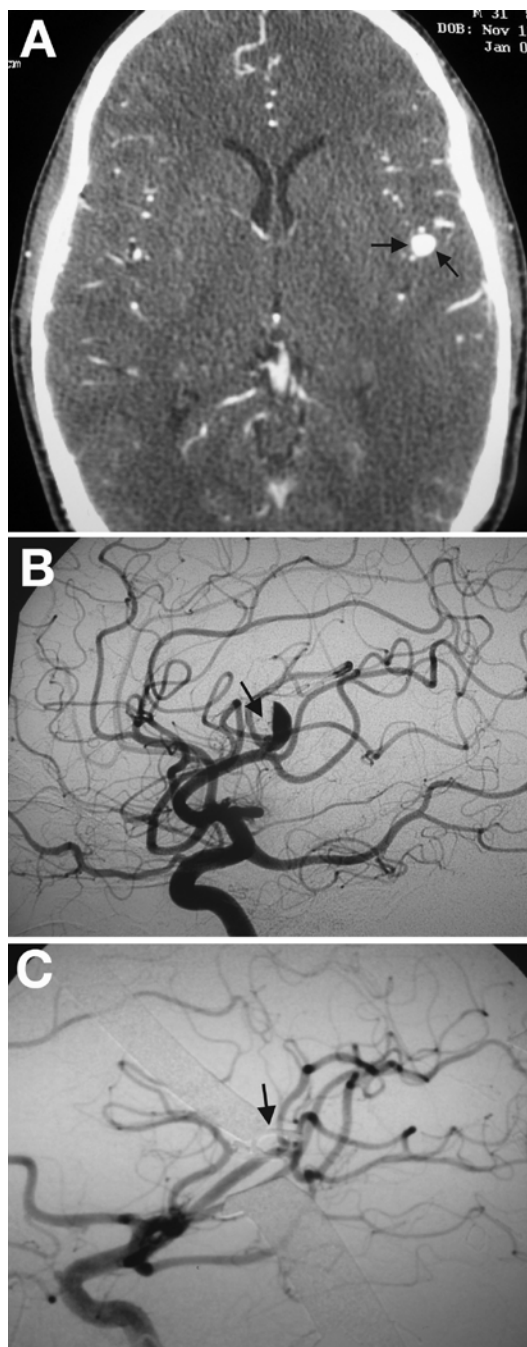


FIG. 4. Axial contrast-enhanced CT scan (A) demonstrates a peripheral MCA aneurysm (arrows) in a patient presenting with SAH. Lateral digital subtraction angiographic image (B) shows partial thrombosis of the lesion (arrow). Intraoperative angiographic image (C) demonstrates adequate vascular reconstruction using a fenestrated, bayoneted clip that incorporates one of the main MCA branches at the level of the aneurysm into the fenestration (arrow).

dition, for those aneurysms not amenable to clip reconstruction, open surgery permits distal revascularization in most cases, limiting the risk of associated ischemic injury. Because endovascular parent artery occlusion typically requires the deposition of coils over some length of the vessel, this technique can result in the unnecessary occlusion of critical perforating arteries that probably could be spared by a strategically placed aneurysm clip.

In our experience, roughly one-half of those aneurysms that were explored surgically could be reconstructed with clips. It was often difficult to predict in advance which aneurysms would be amenable to clip reconstruction, and several large or giant thrombotic lesions were unexpectedly found to be readily “clippable.” In these cases, intraoperative angiography was invaluable in assessing the reconstructed vessel and often resulted in clip repositioning or the placement of additional clips. Overall, using clip reconstruction, end-to-end reanastomosis, and coil placement when feasible, we were able to preserve the parent artery in 38 (63%) of the aneurysms treated in our series. Based on this result, we question the appropriateness of an approach that calls universally for endovascular parent artery occlusion without revascularization, as has been advocated in the past by some groups.^{3,10}

Revascularization Techniques and Rationale

It has been argued that some peripheral aneurysms, particularly those that have reached large or giant size, have altered distal flow in the parent artery, resulting in an increased likelihood of tolerance to vascular occlusion.³ Nevertheless, many reports of parent artery occlusion have described resultant ischemic injuries of varying severity, and it is unclear why attempted distal revascularization would not be the optimal approach for these lesions.^{1–3,10,19,32,33,35} Peripheral aneurysms in certain locations, such as those involving the proximal segments of the PICA, may have critically important perforating arteries arising from the aneurysm itself.^{1,15,25,26} In such cases, parent artery occlusion without revascularization may have severe consequences. We would suggest that the potentially catastrophic neurological complications associated with such a brainstem injury warrant an attempt at revascularization whenever parent artery occlusion is planned for these patients.

The unexpectedly large caliber of the parent artery that was often associated with peripheral intracranial aneurysm development in our series has not been emphasized in the literature. It is possible that the unusually large size of the vessel given its peripheral location may have resulted in, or from, an altered hemodynamic stress that encouraged development of the aneurysm. This large size of the involved vessel has further discouraged us from sacrificing the parent artery without revascularization, considering the concern for a potentially significant ischemic injury resulting from the occlusion of such a large peripherally situated vessel.

Conclusions

Relatively few patients develop peripheral intracranial aneurysms. Because these lesions differ from typi-

could most likely be managed today with this technique. For cases in which endovascular treatment is limited to parent artery occlusion, we have favored open surgical exploration because many of these aneurysms can be reconstructed with preservation of the parent artery. In ad-

cal saccular intracranial aneurysms, they demand unique management considerations. We describe an unusually large series of 60 peripheral intracranial aneurysms. In general, microsurgical exploration was favored over endovascular parent artery occlusion in this series because of the potential for direct clip reconstruction with preservation of the parent artery or distal revascularization when vascular sacrifice was necessary.

The following points are underscored. In comparison with more common saccular aneurysms arising on the circle of Willis, peripherally situated aneurysms tend to be very wide necked or truly fusiform, and tend to reach a larger size before diagnosis. The involved parent artery is often of larger caliber than might be expected, considering its peripheral location in these cases. Combining surgical and endovascular techniques, parent artery preservation was possible in > 60% of cases in this series. When it was necessary to sacrifice the parent artery, the use of distal revascularization was safe and highly effective in preventing distal ischemic injury. Using a thoughtful, individualized approach, a successful outcome was achieved for most of the patients in our series.

Disclaimer

The authors report no conflict of interest concerning the materials or methods used in this study or the findings specified in this paper.

Acknowledgments

The authors acknowledge Jody Lowary, C.N.N.P., for her expert nursing assistance with these patients. We also thank Chris Gralapp for her excellent artwork.

References

1. Ali MJ, Bendok BR, Tawk RG, Getch CC, Batjer HH: Trapping and revascularization for a dissecting aneurysm of the proximal posteroinferior cerebellar artery: technical case report and review of the literature. **Neurosurgery** **51**:258–262, 2002
2. Anson JA, Lawton MT, Spetzler RF: Characteristics and surgical treatment of dolichoectatic and fusiform aneurysms. **J Neurosurg** **84**:185–193, 1996
3. Biondi A, Jean B, Vivas E, Le Jean L, Boch AL, Chiras J, et al: Giant and large peripheral cerebral aneurysms: etiopathologic considerations, endovascular treatment, and long-term follow-up. **AJNR Am J Neuroradiol** **27**:1685–1692, 2006
4. Chapot R, Houdart E, Saint-Maurice JP, Aymard A, Mounayer C, Lot G, et al: Endovascular treatment of cerebral mycotic aneurysms. **Radiology** **222**:389–396, 2002
5. Chun JY, Smith W, Halbach VV, Higashida RT, Wilson CB, Lawton MT: Current multimodality management of infectious intracranial aneurysms. **Neurosurgery** **48**:1203–1214, 2001
6. Cloft HJ, Kallmes DF, Jensen ME, Lanzino G, Dion JE: Endovascular treatment of ruptured, peripheral cerebral aneurysms: parent artery occlusion with short Guglielmi detachable coils. **AJNR Am J Neuroradiol** **20**:308–310, 1999
7. Day AL, Gaposchkin CG, Yu CJ, Rivet DJ, Dacey RG Jr: Spontaneous fusiform middle cerebral artery aneurysms: characteristics and a proposed mechanism of formation. **J Neurosurg** **99**:228–240, 2003
8. Drake CG, Peerless SJ: Giant fusiform intracranial aneurysms: review of 120 patients treated surgically from 1965 to 1992. **J Neurosurg** **87**:141–162, 1997
9. Dolenc V: Treatment of fusiform aneurysms of the peripheral cerebral arteries. Report of two cases. **J Neurosurg** **49**:272–277, 1978
10. Eckard DA, O'Boynick PL, McPherson CM, Eckard VR, Han P, Arnold P, et al: Coil occlusion of the parent artery for treatment of symptomatic peripheral intracranial aneurysms. **AJNR Am J Neuroradiol** **21**:137–142, 2000
11. Fujimura M, Nishijima M, Midorikawa H, Umezawa K, Hayashi T, Kaimori M: Fatal rupture following intra-aneurysmal embolization for the distal posterior inferior cerebellar artery aneurysm with parent artery preservation. **Clin Neuro Neurosurg** **105**:117–120, 2003
12. Hallacq P, Piotin M, Moret J: Endovascular occlusion of the posterior cerebral artery for the treatment of p2 segment aneurysms: retrospective review of a 10-year series. **AJNR Am J Neuroradiol** **23**:1128–1136, 2002
13. Hodes JE, Aymard A, Gobin YP, Rufenacht D, Bien S, Reizine D, et al: Endovascular occlusion of intracranial vessels for curative treatment of unclippable aneurysms: report of 16 cases. **J Neurosurg** **75**:694–701, 1991
14. Jean WC, Walski-Easton S, Nussbaum ES: Multiple intracranial aneurysms as a delayed complication of atrial myxoma: case report. **Neurosurgery** **49**:200–203, 2001
15. Kanou Y, Arita K, Kurisu K, Ikawa F, Eguchi K, Monden S, et al: Dissecting aneurysm of the peripheral posterior inferior cerebellar artery. **Acta Neurochir (Wien)** **142**:1151–1156, 2000
16. Lazinski D, Willinsky RA, TerBrugge K, Montanera W: Dissecting aneurysms of the posterior cerebral artery: angioarchitecture and a review of the literature. **Neuroradiology** **42**:128–133, 2000
17. Lewis SB, Chang DJ, Peace DA, Lafrentz PJ, Day AL: Distal posterior inferior cerebellar artery aneurysms: clinical features and management. **J Neurosurg** **97**:756–766, 2002
18. Lubicz B, Leclerc X, Gauvrit JY, Lejeune JP, Pruvo JP: Endovascular treatment of peripheral cerebellar artery aneurysms. **AJNR Am J Neuroradiol** **24**:1208–1213, 2003
19. Mawad ME, Klucznik RP: Giant serpentine aneurysms: radiographic features and endovascular treatment. **AJNR Am J Neuroradiol** **16**:1053–1060, 1995
20. Mizutani T, Kojima H, Asamoto S: Healing process for cerebral dissecting aneurysms presenting with subarachnoid hemorrhage. **Neurosurgery** **54**:342–348, 2004
21. Mizutani T, Kojima H, Asamoto S, Miki Y: Pathological mechanism and three-dimensional structure of cerebral dissecting aneurysms. **J Neurosurg** **94**:712–717, 2001
22. Mizutani T, Miki Y, Kojima H, Suzuki H: Proposed classification of nonatherosclerotic cerebral fusiform and dissecting aneurysms. **Neurosurgery** **45**:253–260, 1999
23. Nakasu S, Kaneko M, Matsuda M: Cerebral aneurysms associated with Behcet's disease: a case report. **J Neurol Neurosurg Psychiatry** **70**:682–684, 2001
24. Nakatomi H, Segawa H, Kurata A, Shiokawa Y, Nagata K, Kamiyama H, et al: Clinicopathological study of intracranial fusiform and dolichoectatic aneurysms: insight on the mechanism of growth. **Stroke** **31**:896–900, 2000
25. Nussbaum ES, Madison MT, Myers ME, Goddard J, Janjua TM: Dissecting aneurysms of the posterior inferior cerebellar artery. **J Neurosurg** **109**:23–27, 2008
26. Nussbaum ES, Mendez A, Camarata P, Sebring LA: Surgical management of fusiform aneurysms of the peripheral posterior-inferior cerebellar artery. **Neurosurgery** **53**:831–834, 2003
27. Olmsted WW, McGee TP: The pathogenesis of peripheral aneurysms of the central nervous system: a subject review from the AFIP. **Radiology** **123**:661–666, 1977
28. Oran I, Memis A, Parildar M, Yuntun N: Multiple intracranial aneurysms in polyarteritis nodosa: MRI and angiography. **Neuroradiology** **41**:436–439, 1999
29. Ross IB, Weill A, Piotin M, Moret J: Endovascular treatment

Peripheral aneurysms

- of distally located giant aneurysms. **Neurosurgery** **47**:1147–1153, 2000
30. Sakaki T, Morimoto T, Utsumi S: Cerebral transmural angitis and ruptured cerebral aneurysm in patients with systemic lupus erythematosus. **Neurochirurgia (Stuttg)** **33**:132–135, 1990
 31. Sanai N, Quinones-Hinojosa A, Gupta NM, Perry V, Sun PP, Wilson CB, et al: Pediatric intracranial aneurysms: durability of treatment following microsurgical and endovascular management. **J Neurosurg** **104**:82–89, 2006
 32. Sciubba DM, Gallia GL, Recinos P, Garonzik IM, Clatterbuck RE: Intracranial aneurysm following radiation therapy during childhood for a brain tumor. **J Neurosurg** **105 (2 Suppl)**:134–139, 2006
 33. Seoane ER, Tedeschi H, de Oliveira E, Siqueira MG, Calderon GA, Rhoton AL Jr: Management strategies for posterior cerebral artery aneurysms: a proposed new surgical classification. **Acta Neurochir (Wien)** **139**:325–331, 1997
 34. Terasaka S, Sawamura Y, Kamiyama H, Fukushima T: Surgical approaches for the treatment of aneurysms on the P2 segment of the posterior cerebral artery. **Neurosurgery** **47**:359–364, 2000
 35. Vishteh AG, Smith KA, McDougall CG, Spetzler RF: Distal posterior cerebral artery revascularization in multimodality management of complex peripheral posterior cerebral artery aneurysms: technical case report. **Neurosurgery** **43**:166–170, 1998
 36. Yamamoto I, Tsugane R, Ohya M, Sato O, Ogura K, Hara M: Peripheral aneurysms of the posterior inferior cerebellar artery. **Neurosurgery** **15**:839–845, 1984
 37. Yamaura I, Tani E, Yokota M, Nakano A, Fukami M, Kaba K, et al: endovascular treatment of ruptured dissecting aneurysms aimed at occlusion of the dissected site by using Guglielmi detachable coils. **J Neurosurg** **90**:853–856, 1999

Manuscript submitted February 27, 2008.

Accepted June 20, 2008.

Please include this information when citing this paper: published online October 17, 2008; DOI: 10.3171/2008.6.JNS0814.

Address correspondence to: Eric S. Nussbaum, M.D., 3033 Excelsior Boulevard, Suite 403, Minneapolis, Minnesota 55416. email: lnussbaum@comcast.net.