

Vascular Malformations of the Brain

BY ERIC S. NUSSBAUM, M.D.

Vascular malformations of the brain are a heterogeneous group of disorders involving the blood vessels of the brain. These entities are relatively rare; therefore, most primary care physicians are somewhat unfamiliar with their clinical implications and management. Vascular malformations of the brain range from the completely benign capillary telangiectasia to the potentially fatal arterio-venous malformation. This article reviews the distinct natural histories, etiologies and treatments of four major types of malformations: capillary telangiectasia, developmental venous anomaly, cavernous malformation and arteriovenous malformation.

Vascular malformations of the brain represent a heterogeneous group of disorders that have very different natural histories and clinical implications.^{1,2} These malformations range from completely benign congenital lesions diagnosed incidentally by magnetic resonance imaging (MRI) or postmortem to potentially life-threatening lesions that require aggressive neurosurgical intervention. Vascular malformations of the brain occur in up to 1% of the population; most are benign and will never require treatment.^{1,2} With the ever-improving quality of MR imaging and as more patients are undergoing MR imaging of the brain for routine, often unrelated reasons, more vascular malformations are being identified as an incidental finding. As a result, physicians in a variety of specialties are encountering patients with these lesions. This article briefly describes the spectrum of vascular malformations of the brain that may be encountered in medical practice and their natural history and management recommendations.

Capillary Telangiectasia

The most benign of all malformations of the brain is capillary telangiectasia. Capillary telangiectasias are small areas of abnormal capillaries within otherwise normal brain tissue. These lesions are almost certainly congenital in origin and most commonly are identified as an incidental

finding at the time of autopsy, although high-quality MRI will occasionally reveal a capillary telangiectasia.^{1,2} Although capillary telangiectasias can develop anywhere in the brain, they seem to have a predilection for the pons.^{1,2} These lesions generally do not require treatment. An occasional follow-up imaging study may be appropriate, depending on the case.

Developmental Venous Anomaly

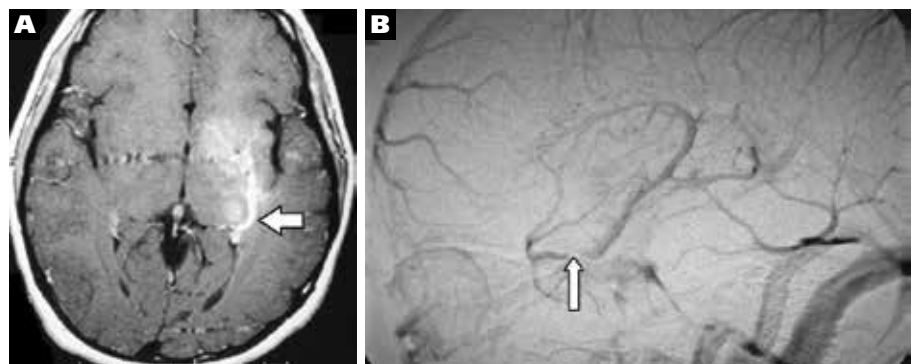
Developmental venous anomalies (DVAs), as their name suggests, are aberrantly formed venous channels within the brain.^{1,3} They are congenital and rarely produce symptoms. Previously, these lesions were known as “venous angiomas,” but the nomenclature has changed to reflect their benign natural history and to

discourage surgeons from contemplating their removal^{3,5} (Figure 1).

Developmental venous anomalies are most commonly identified as an incidental finding on MRI and, in isolation, require no treatment in almost all cases.⁵ We and others have reported rare instances when thrombosis of a portion of a DVA appears to have resulted in symptoms.⁶⁻⁸ Nevertheless, there is rarely a straightforward treatment option other than antiplatelet therapy, and such cases remain predominantly of academic interest. The most important thing for clinicians to know about DVAs is that they frequently coexist with cavernous malformations of the brain.⁹ In those instances, it is almost always the cavernous malformation that causes symptoms—typically, bleeding or seizures. If the cav-

FIGURE 1

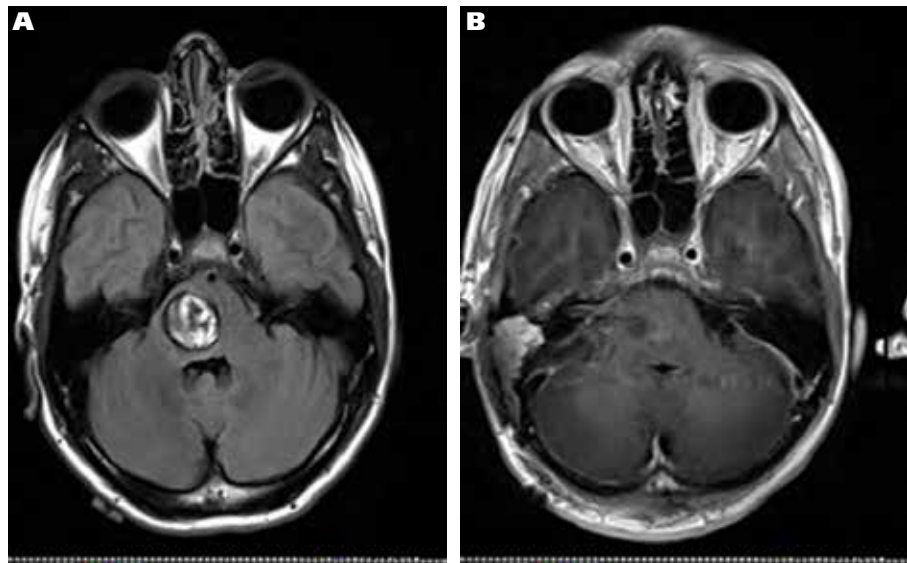
Developmental Venous Anomaly



A. Axial MRI demonstrating a large developmental venous anomaly (arrow) involving the left basal ganglia. B. Diagnosis confirmed by conventional catheter angiography.

FIGURE 2

Brainstem Before and After Surgery to Remove Cavernous Malformation



A. Axial MRI showing a large cavernous malformation of the brainstem in a young patient presenting with acute neurological deficit. B. Corresponding postoperative MRI showing complete resection of the lesion through a presigmoid approach. The patient had no postoperative deficit.

ernous malformation needs to be treated, the surgeon should leave the DVA intact as this structure represents the “normal” venous drainage pathway for the patient.^{4,5} Interruption of the DVA can interfere with venous outflow from that portion of the brain, resulting in venous hypertension, venous ischemia, hemorrhage and even death.

Cavernous Malformations

Cavernous malformations (CMs) are a fascinating and poorly understood group of vascular malformations that can occur anywhere in the brain. CMs are low-flow channels of aberrant blood vessels without normal intervening brain parenchyma.^{1,2,10-12} They appear to develop after birth and may be associated with previous head injury, other pre-existing conditions, and surgery or radiation.¹⁰⁻¹² There may be a strong genetic basis for CMs in some patients, and these individuals may have multiple CMs.¹³

Patients with CMs may present with seizures, headaches, bleeding and, rarely, mass effect if the CM is large or located in a critical portion of the brain (Figures 2 and 3). Cavernous malformations generally are diagnosed by MRI and are char-

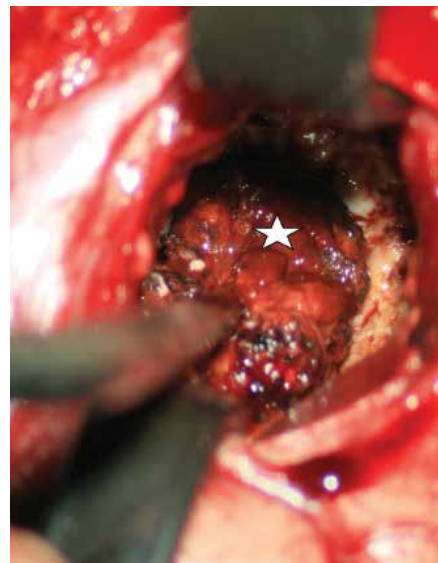
acterized as well-circumscribed lesions with a classic hemosiderin ring. There is great controversy regarding the actual annual bleeding risk for CMs, with estimates ranging from 1% per year to as high as 39% per year in posterior fossa lesions.¹⁰⁻¹² In our practice, we generally tell patients the risk of bleeding is 1% to 2% per year.

Most episodes of bleeding from CMs are not life-threatening. Instead, bleeding usually results in the development of a focal neurological deficit such as weakness or language difficulty and possibly a seizure. Over time, as the blood is reabsorbed, the deficit will improve, although the patient may be left with some slight deficit. Before the MRI era, many patients with CMs were misdiagnosed with multiple sclerosis (MS) because their lesions would bleed intermittently, producing a gradual, step-wise decline in neurological function, similar to that seen with typical MS.

The treatment of CMs generally consists of either observation with follow-up serial imaging studies or open microsurgical removal.¹⁴ Stereotactic radiosurgery has been used in select cases and at select centers; but most large neurovascular centers do not use radiosurgery for this le-

FIGURE 3

Removal of Cavernous Malformation



Operative photomicrograph reveals a large cavernous malformation (white star) being removed from its bed via a limited transcortical approach.

sion, and there has been some suggestion that people with CMs may be at high risk for developing post-radiosurgery radiation injury.^{10-12,14,15}

Patients with CMs generally should be evaluated by a vascular neurosurgeon who has expertise in treating these lesions. He or she can discuss the expected natural history and the advisability of surgical removal.

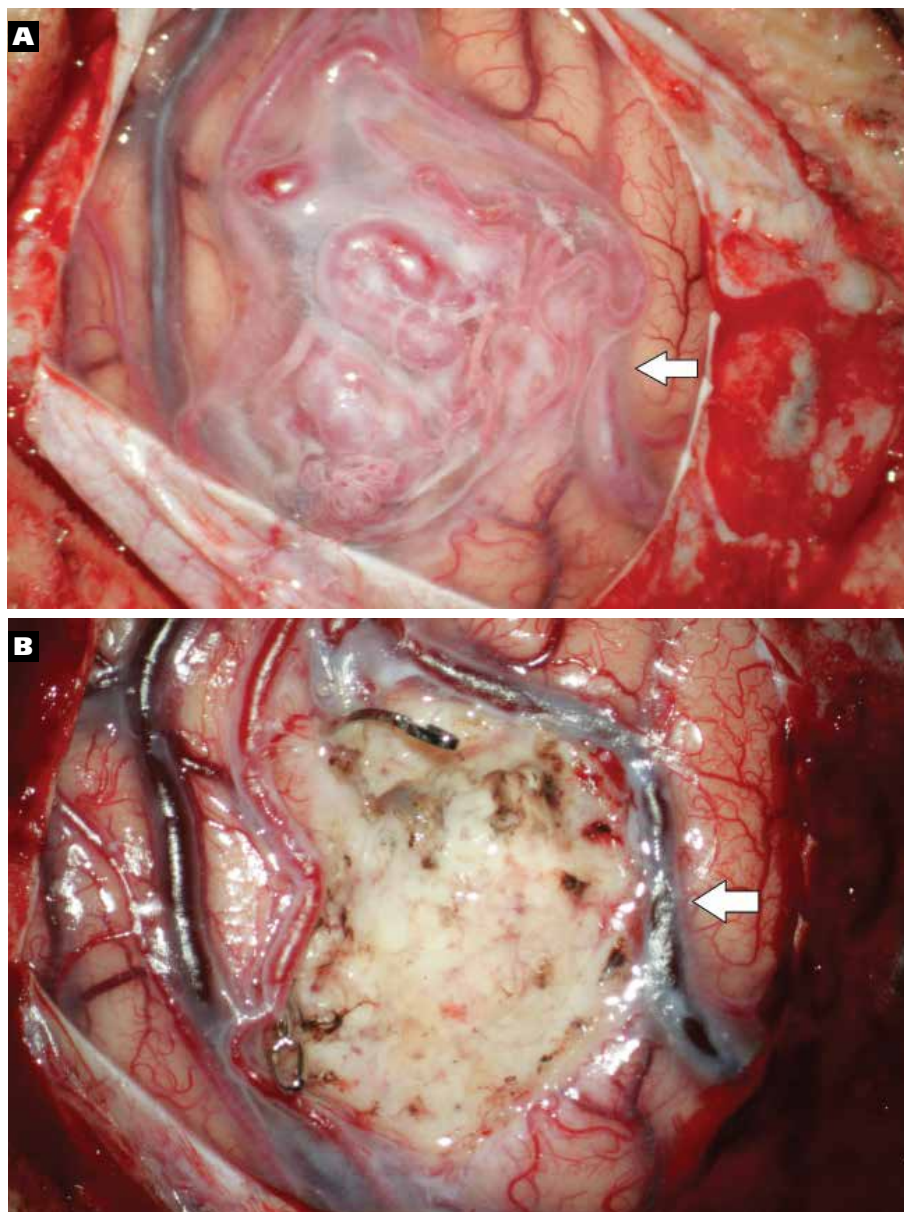
Arteriovenous Malformations

Arteriovenous malformations (AVMs) are probably the most recognized of the brain vascular malformations. They represent serpigenous collections of abnormal, congenital blood vessels, often with normal intervening brain parenchyma.¹² They are characterized by shunting of blood from the arterial to the venous system without normal intervening capillary channels (Figure 4). This can result in a very dangerous, high-flow system with the potential for devastating, life-threatening hemorrhage.

Arteriovenous malformations can present with bleeding, seizures or neurological deficit resulting from a “cerebral steal” phenomenon, in which the high flow through the malformation may actually

FIGURE 4

Arteriovenous Malformations



A. A large arteriovenous malformation (AVM) is seen on the cortical surface of the brain in this operative photomicrograph. Note the arterIALIZED vein (arrow), which appears red at the beginning of the procedure.
 B. Following complete removal of the AVM, the resection bed is seen, and the vein (arrow) has now turned blue.

rob the normal neighboring brain of its blood supply, resulting in local cerebral dysfunction.¹⁶⁻¹⁸ They are typically well-visualized with MRI, which demonstrates the classic tangle of abnormal blood vessels. The risk of rupture for a given AVM depends on a number of factors; estimated annual hemorrhage rates range from 1% to more than 30%.¹⁶⁻¹⁸

Bleeding from AVMs tends to be lobar, into the brain substance itself, and often occurs in young adults. Bleeding is life-threatening in more than 10% of cases.¹⁶⁻¹⁸

Each case requires evaluation by a multidisciplinary team.¹⁹

AVMs can be treated in various fashions or using a combination of therapies.²⁰ Some lesions—for example, unruptured AVMs in elderly patients discovered incidentally—are managed with observation and serial imaging, the goal being to watch for a change in blood flow or the development of associated aneurysms. If the venous outflow of the AVM shows a narrowing or the development of an an-

eurysm, treatment may be considered to avoid rupture.

Some patients, particularly those with malformations that are smaller or in critical locations, may be appropriate for stereotactic radiosurgery.²¹⁻²³ This therapy has emerged as an important option for such patients. Stereotactic radiosurgery can cure smaller lesions in more than 90% of cases and may obviate the need for an invasive procedure. At the same time, with stereotactic radiosurgery it can take longer than a year to eradicate most AVMs and during that time the patient remains at risk for bleeding.

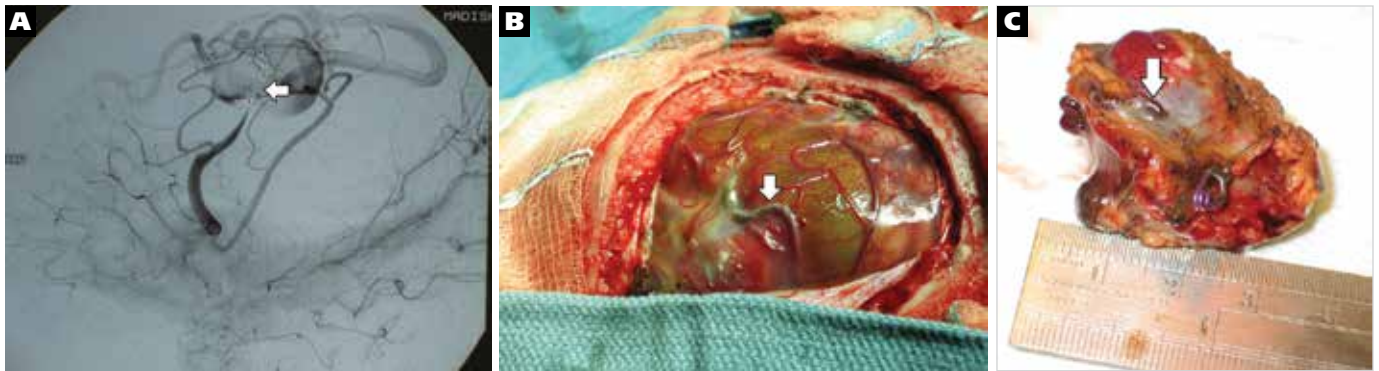
Endovascular embolization is another option for treating AVMs either as an attempt to treat the lesion without surgery or as an adjunct to stereotactic radiosurgery or open surgery.²⁴⁻²⁶ Embolization involves placing a microcatheter in the feeding arteries (or draining veins) of a malformation and then injecting a glue-like substance or embolic material to decrease flow through the malformation (Figure 5). In our experience, most AVMs cannot be cured with simple embolization and will require some additional therapy, although some groups have reported success with this option, particularly when treating AV fistulae, the simplest type of AVM.²⁴⁻²⁶

Open microsurgical excision is the final option for treating AVMs. Most centers use the Spetzler-Martin grading system to stratify surgical risk, with the simplest lesions assigned a Grade I and the most complex a Grade V.²⁷ These are complex surgeries that should be performed by vascular neurosurgeons with expertise in this area. Every effort must be made to limit intraoperative bleeding and to remove the malformation as quickly and efficiently as possible. Preoperative embolization may be very helpful in this regard.

Because of the controversy surrounding the natural history of these lesions and the many complex, sometimes overlapping treatment options, patients with AVMs need to be evaluated by a multidisciplinary service that can offer open microsurgery, embolization or stereotactic radiosurgery, alone or in combination.

FIGURE 5

Arteriovenous Malformations



A. Preoperative arteriographic image shows a large and complex arteriovenous malformation (AVM) in a young child. Embolic coils (arrow) have been placed in the feeding artery to decrease flow into the large venous varix (circular shaped structure seen under the coils). B. Operative view at the beginning of the procedure showing the very abnormal appearing brain and the coils (arrow) within the feeding artery. C. Pathological specimen following complete extirpation of the AVM again show the coils (arrow) within the feeding artery.

Conclusion

Vascular malformations of the brain represent a fascinating collection of diverse lesions that primary care physicians occasionally encounter and that vascular neurosurgeons frequently encounter. Because these lesions are so diverse in terms of natural history and because there are so many treatment options, most patients should be evaluated by an experienced vascular neurosurgeon who can determine a treatment plan. In patients with simple telangiectasias and DVAs, occasional follow-up can be coordinated through the primary care physician's office, and the patient can be reassured that there is little, if any, chance of a problem related to the lesion. Patients with CMs or true AVMs require a more detailed evaluation and may benefit from intervention to decrease the risk of bleeding, eliminate seizures or reduce mass effect. **MM**

Eric Nussbaum is director of Minnesota Neurovascular and Skull Base Surgery in St. Louis Park.

REFERENCES

- McCormick WF. The pathology of vascular "arteriovenous" malformations. *J Neurosurg.* 1966;24(4):807-16.
- McCormick WF. Pathology of vascular malformation of the brain. In: Wilson CB and Stein BM, editors. *Intracranial Arteriovenous Malformation.* Baltimore: Williams and Wilkins, 1984:44-63.
- Lasjaunias P, Burrows P, Planet C. Developmental venous anomalies (DVA): the so-called venous angioma. *Neurosurg Rev.* 1986;9(3):233-42.
- Nussbaum ES, Heros RC, Madison MT, Awashi D, Truwit CL. The pathogenesis of arteriovenous malformations: insights provided by a case of multiple arteriovenous malformations developing in relation to a developmental venous anomaly. *Neurosurgery.* 1998;43(2):347-52.
- Truwit CL. Venous angioma of the brain: history, significance, and imaging findings. *AJR Am J Roentgenol.* 1992;159(6):1299-307.
- Nussbaum ES, Defillo A, Nussbaum LA. Developmental venous anomaly associated with Hemi-Parkinson's Syndrome. *Cureus.* 2013;5(1):e80.
- Kalia LV, Mozessohn L, Aviv RI, et al. Hemichorea-hemiballism associated with hyperglycemia and a developmental venous anomaly. *Neurology.* 2012;78(11):838-9.
- Guhl S, Kirsch M, Lauffer H, Fritsch M, Schroeder. Unusual mesencephalic developmental venous anomaly causing obstructive hydrocephalus due to aqueduct stenosis. *J Neurosurg Pediatr.* 2011;8(4):407-10.
- Wilms G, Bleus E, Demaerel P, et al. Simultaneous occurrence of developmental venous anomalies and cavernous angiomas. *AJNR Am J Neuroradiol.* 1994;15(7):1247-54.
- Maraire JN, Awad IA. Intracranial cavernous malformations: lesion behavior and management strategies. *Neurosurgery.* 1995;37(4):591-605.
- Moriarty JL, Wetzel M, Clatterbuck RE, et al. The natural history of cavernous malformations: a prospective study of 68 patients. *Neurosurgery.* 1999;44(6):1166-71.
- Reid PJ, Campbell SS, Vates GE, Allende R. Extreme de novo appearance of cerebral cavernous malformations: case report. *Neurosurgery.* 2008;62(4):E969-70.
- Dashti SR, Hoffer A, Hu YC, Selman WR. Molecular genetics of familial cerebral cavernous malformations. *Neurosurg Focus.* 2006;21(1):e2.
- Pandey P, Westbroek, E, Gooderham P, Steinberg GK. Cavernous malformation of brainstem, thalamus, and basal ganglia: a series of 176 patients. *Neurosurgery.* 2013;72(4):573-89.
- Gabor N, Razak A, Rowe JG, et al. Stereotactic radiosurgery for deep-seated cavernous malformations: a move toward more active, early intervention. *J Neurosurg.* 2010;113(4):691-9.
- Gross BA, Du R. Natural history of cerebral arteriovenous malformations: a meta-analysis. *J Neurosurg.* 2013;118(2):437-43.
- Da Costa L, Wallace CM, Terbrugge K, et al. A single-center, prospective analysis of the natural history of hemorrhage from brain arteriovenous malformations with or without associated aneurysms. *Neurosurgery.* 2005;57(2):396-7.
- Hernesniemi JA, Dashti R, Juvela S, et al. Natural history of brain arteriovenous malformations: a long-term follow-up study of 238 patients. *Neurosurgery.* 2008;62(6):823-9.
- Brown RD Jr. Unruptured brain AVMs: to treat or not to treat. *Lancet Neurol.* 2008;7(3):195-6.
- Bejjani JV, van der Worp B, Buis DR, et al. Treatment of brain arteriovenous malformations: a systematic review and meta-analysis. *JAMA.* 2011;306(18):2011-9.
- Murray G, Brau RH. A 10-year experience of radiosurgical treatment for cerebral arteriovenous malformations: a perspective from a series with large malformations. *J Neurosurg.* 2011;115(2): 337-46.
- Pollock BE, Gorman DA, Coffey RJ. Patient outcomes after arteriovenous malformation radiosurgical management: results based on a 5- to 14-year follow-up study. *Neurosurgery.* 2003;52(6):1291-7.
- Kondziolka D, Lunsford LD, Flickinger JC, Kestle JR. Reduction of hemorrhage risk after stereotactic radiosurgery for cavernous malformations. *J Neurosurg.* 1995;83(5):825-31.
- Lopes DK, Bradley B, Wells K. Onyx embolization of arteriovenous malformations using 2 microcatheters. *Neurosurgery.* 2010;66(3):616-9.
- Jahan R, Murayama Y, Gobin YP, Duckwiler GR, Vinters HV, Viñuela F. Embolization of arteriovenous malformations with Onyx: clinicopathological experience in 23 patients. *Neurosurgery.* 2001;48(5):984-95.
- Starke RM, Komotar RJ, Otten ML, et al. Adjuvant embolization with N-butyl cyanoacrylate in the treatment of cerebral arteriovenous malformations: outcomes, complications, and predictors of neurologic deficits. *Stroke.* 2009;40(8):2783-90.
- Spetzler RF, Martin NA. A proposed grading system for arteriovenous malformations. *J Neurosurg.* 1986;65(4):476-83.